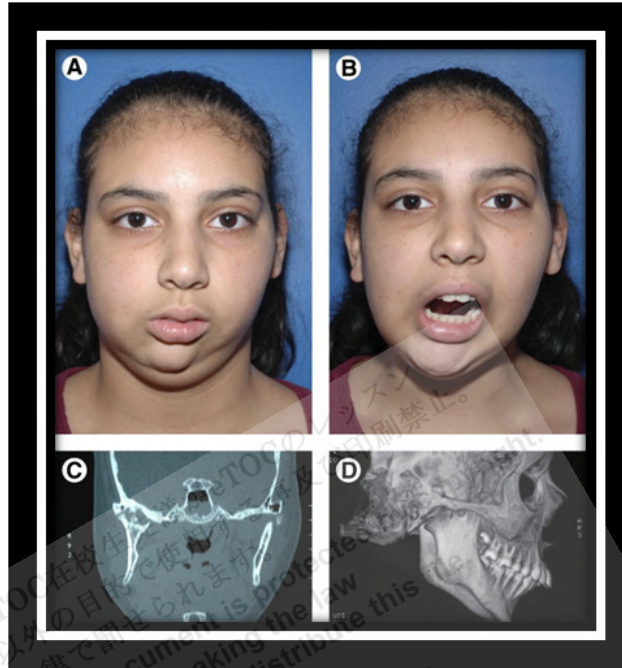


# Ankylosis of the Temporomandibular Joint (TMJ)



<http://ars.els-cdn.com/content/image/1-s2.0-S0278239109010957-gr2.jpg>

*Ankylosis of the TMJ is immobility or fusion of the joint.*

Ankylosis of the TMJ most often results from trauma or infection, but it may be **congenital** or a result of RA. Chronic, painless limitation of motion occurs. When ankylosis leads to arrest of condylar growth, facial asymmetry is common. **Intra-articular** (true) ankylosis must be distinguished from **extra-articular** (false) ankylosis, which may be caused by enlargement of the **coronoid process**, depressed fracture of the **zygomatic arch**, or scarring resulting from surgery, irradiation, or infection. In most cases of true ankylosis, x-rays of the joint show loss of normal bony architecture.

Treatment may include a **condylectomy** if the ankylosis is intra-articular or an **ostectomy** of part of the ramus if the coronoid process and **zygomatic arch** are also affected. Jaw-opening exercises must be done for months to years to maintain the surgical correction, but forced opening of the jaws without surgery is generally ineffective because of bony fusion.